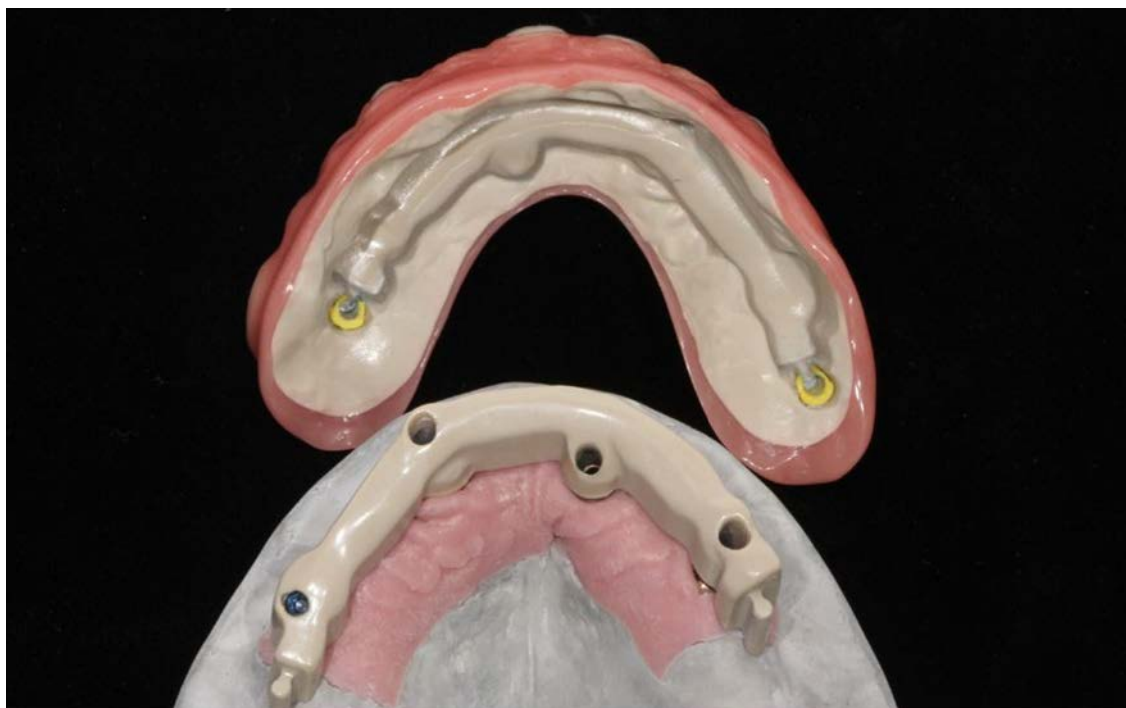

## IMPLANT PROSTHODONTICS

*Summary*

*Treating a patient with a complex combination of implants and prostheses requires a good working relationship between dentist and dental technician. A patient case is used to illustrate how, despite an initially confusing situation, a balanced and aesthetic result can be achieved with consistent backward planning, the application of modern treatment methods and the use of a new framework material.*

*Indices*

*Implant prosthodontics, backward planning, CAD/CAM, three-dimensional diagnostic imaging, metal-free denture, PEEK*

## PEEK – A “new” framework material for metal-free prosthetic treatment

**Bernd Siewert, Helmut Rieger**

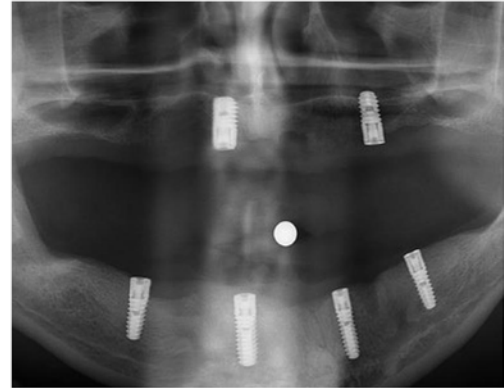
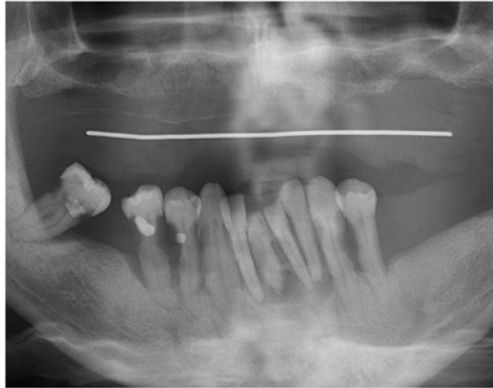
Media interest keeps shifting to new topics, and the same is true of dental prosthodontics, with examples including backward planning, CAD/CAM, navigated implantology, monolithic fabrication. The current focus is on various materials which can be processed using CAD/CAM assisted fabrication. A multitude of both procedures and material variants may be found in implant prosthodontics, in particular. Frameworks made of non-precious metal alloys or titanium have been the materials of choice to date, but metal-free superstructures are now increasingly gaining in importance.

For example, the high-performance polymer polyetheretherketone (PEEK) is ideally suited for a removable or conditionally removable prosthesis. The material has been used in industry for many years, and has also proved its worth in various areas of medicine.<sup>1-3</sup> PEEK is bioinert, tissue-friendly, cytotoxicologically safe, does not conduct electricity and is a thermal insulator.<sup>2</sup> To the authors' knowledge, the partly crystalline high-performance material PEEK, with its good mechanical properties, low weight and excellent chemical stability, is winning over more and more dentists and dental technicians. PEEK frameworks made from industrially manufactured blanks (e.g. Juvora Dental Disc, Juvora Dental Ltd., Lancashire, UK) can now be fabricated using CAD/CAM-aided techniques.

*Introduction*

Fig. 1 Panoramic X-ray of the baseline situation: edentulous maxilla and non-preservable residual teeth in the mandible.

Fig. 2 Following implantation: two implants were inserted into the maxilla and four into the mandible. The mandibular prosthesis was retained during the healing period; this allowed the patient to get used to the "new" situation.



Osseointegration of the implants and the optimum materials are not the only factors of a successful outcome: considered and coordinated working procedures should also be included among them. Long-term success will only be achieved if the criteria for the prosthesis are integrated into the overall implantological concept from the outset. In the authors' view, a sort of hierarchy, in which the dentist alone rules supreme, is not state of the art. More than ever, new technologies and modern material designs require a close working relationship between the treatment partners. A combination of promising criteria will be highlighted using the patient case documented below:

- Considered treatment plan
- Optimal material
- Cooperation between treatment partners

#### Case report Baseline situation

The 41-year-old patient presented at the practice with his mouth in a desperate state. The man's maxilla was edentulous. In the mandible, he showed a decayed residual dentition with severe periodontal damage and correspondingly marked loosening of the teeth. The panoramic X-ray (Fig. 1) showed a severely atrophied alveolar ridge in the maxilla. It also confirmed that the teeth in the maxilla were non-preservable. As a result of the muscular compensation due to years of insufficient occlusal support, there was pronounced facial asymmetry, making it difficult to determine the centric relation and the midline. A considered, stepwise process was required to solve this difficult and initially confusing case. The plan was to fit the patient with implant-supported prostheses. The first step consisted of stabilising the situation. A definitive restoration promising a successful outcome could only be realised after this.

#### Dental treatment segment

Following extraction of all the teeth, the patient was provided with a newly made interim prosthesis for the lower jaw, with his existing prosthesis incorporated into the upper jaw. The fitting of two implants (blueSKY, bredent, Senden) into the maxilla followed after three months. Regions with maximum bone volume were chosen as the implantation sites. A few weeks after this, four implants (blueSKY) were also inserted into the mandible (Fig. 2). The patient's interim prostheses were used during the four-month healing period. No changes were made to the upper jaw prosthesis during this time,

## IMPLANT PROSTHODONTICS

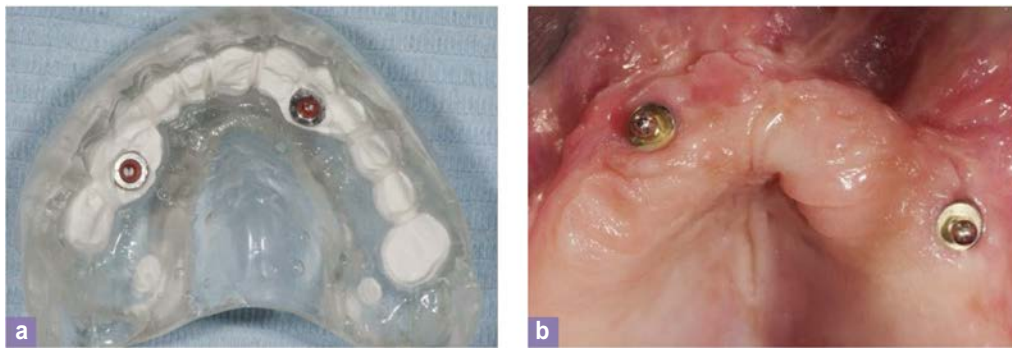


Fig. 3a and b Tooth set-up bases with O-ring attachments formed the basis for an X-ray template (and later also a drilling template) supported by the two implants.

as the implants had been inserted subgingivally. The lower jaw prosthesis was padded with a soft gel (UfiGel SC, Voco, Cuxhaven) in the patient's mouth, the first time due to the bone changes taking place while the extraction wounds healed, and a second time to protect the implants. In the maxilla, however, the two implants could not guarantee adequate superstructure stability. Two additional implants are therefore to be inserted at a later time. The template-assisted method was selected to allow this to be undertaken safely and without major surgery.

A wax-up in the ideal prosthetic situation provided the basis. To stabilise it, deep-drawn bases were fabricated and O-ring attachments integrated into them. An X-ray template (also with O-ring attachments) was fashioned for the maxilla, based on the set-up of the teeth as verified in the patient's mouth (Fig. 3a). The available implants held the template in place during the three-dimensional X-ray (DVT, Galileos compact, Sirona, Bensheim) in the patient's mouth (Fig. 3b).

Analysis of the DVT data set showed considerable discrepancy between the height of the alveolar ridge and the desired prosthetic situation (Fig. 4a and b). A removable solution was unavoidable; consequently, bone augmentation in the form of a sinus lift in the maxilla made no sense. To provide the patient with a comfortable solution including adequate lip support, a connecting bar prosthesis supported by four implants was chosen for the definitive maxillary reconstruction. This removable denture facilitates good prosthesis hygiene, and was to be of palate-less design. A fixed bridge, screw-retained and thus conditionally removable, seemed to be more advantageous for the mandible. The DICOM data from the DVT images were imported into the SKYPlanX (bredent) planning software, and two additional implants placed virtually into the optimum sites (Fig. 4c).

The anatomically and prosthetically ideal implant positions were transferred to the drilling template and the implants inserted into the jaw by navigated placement. A circular scalpel, which fits exactly into the guide holes of the drilling template, was pressed down gently to induce superficial bleeding; the template was then removed to check whether the exit point lies within the keratinised mucosa. This was not the case in the region of tooth 15, so that a straight incision 15 mm in length was made with the scalpel at the height of the palatal circumference and the mucoperiosteal flap opened out in the vestibular direction. This type of intelligent incision is possible only

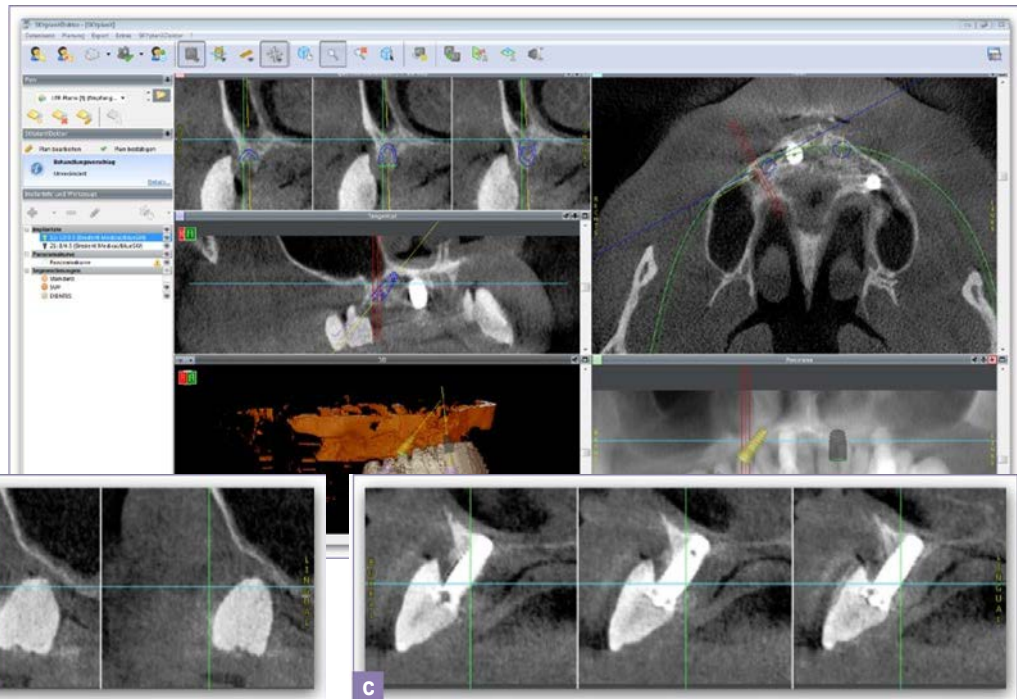


Fig. 4a Transverse section at the height of the left molar: large, pneumatized maxillary sinus and pronounced atrophy of the alveolar process

Fig. 4b Transverse section at the height of the osseointegrated implant in the region of tooth 12 with ball attachment and O-ring.

Fig. 4c Some things have become indispensable: three-dimensional implant planning in the maxilla.

with a drilling template-assisted procedure. When the implantation is done freehand, the incision is made arbitrarily in the centre of the alveolar ridge, which makes targeted soft tissue management impossible.

Pressure on the inserted implants during the healing period was avoided by grinding the underside of the interim prosthesis to the correct shape. The O-ring attachments that were already in place held the prosthesis securely in the mouth (Fig. 5). As is usual with this “minimally invasive” procedure, the patient had no problems or swellings after the surgery. Seven months later, the keratinised cuff at the implant in the region of tooth 15 had stayed at optimum volume, an important factor in the long-term success of the implant. The volume was considerably lower around implant 24, which had been inserted freehand (see Fig. 6a).

### *Prosthetic treatment segment*

The optimum conditions for the start of the restorative therapy were now in place (Fig. 6a and b). PEEK was used as the framework material both for the connecting bar in the maxilla and for the occlusal screw-retained bridge in the mandible. There were a number of reasons for this decision:

- Avoidance of a galvanic element by using a non-conducting material.
- High biocompatibility and the excellent behaviour of soft tissue when in contact with pure, unfilled PEEK.

## IMPLANT PROSTHODONTICS

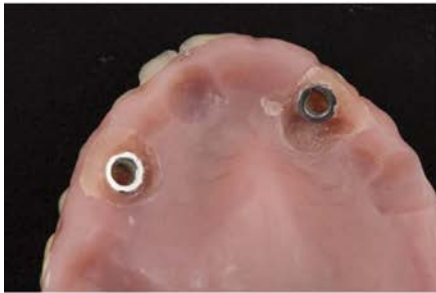

Fig. 5 The undersides of the interim prostheses were ground to shape (maxilla shown here) following insertion of the additional implants.

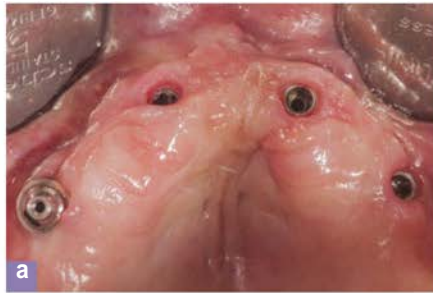

Fig. 6a and b Start of the prosthetic treatment phase: optimum conditions for the reconstruction are apparent seven months after insertion of the implants

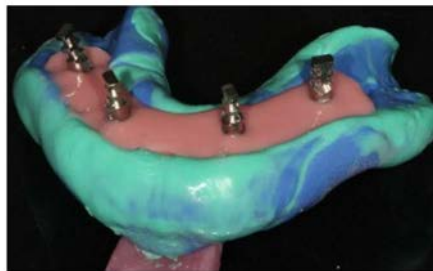
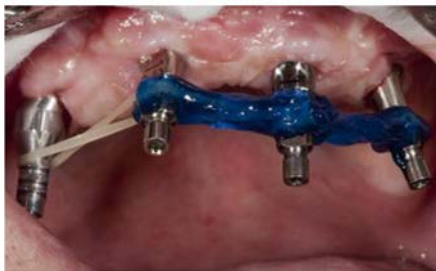
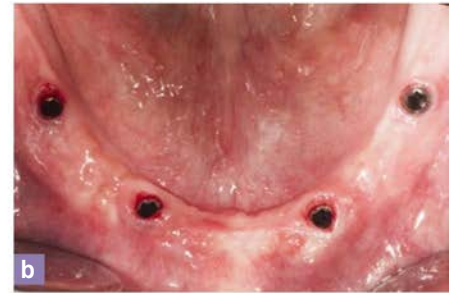
Fig. 7 To ensure precise casting and a tension-free fit of the connecting bar, the implant posts were attached inside the mouth using a plastic splint.

Fig. 8 Constructing the model: a gingival mask is essential for indications of this type.

- Optimum elasticity of the occlusal screw-retained mandibular denture (Juvora Dental Disc has a similar elasticity module to cancellous bone). This compensates for any torsion in the mandibular brace.
- High wearer comfort due to low prosthesis weight.
- Virtually metal-free (only titanium abutments).
- The veneers deliver a good aesthetic result.
- Comfortable bite for the patient.
- Shock-absorbing properties to protect the implants.

Lack of tension is a requirement with reconstructions of this type. To ensure it, the prosthesis was cast following intraoral splinting of the implant posts and using silicon in an open moulding tray (Fig. 7). The master models were fabricated in the laboratory; in this sort of work, the gum mask is a guarantee for optimum shaping of the underside of the denture (Fig. 8 und 9).

The tooth set-up, already determined during the planning phase, was transferred to the master models and re-verified on the patient. This was necessary as the patient's facial muscles had become visibly relaxed through wearing the fixed full prostheses over the past months (Fig. 10).

The final set-up of the teeth in the upper and lower jaws was scanned in and the STL data imported into the software. The secondary structures could now be modelled virtually. Using the prosthesis teeth displayed by the software as a basis, the structures were made as delicate or as massive as required. The option of displaying the tooth set-up in the software enabled accurate modelling of the diminished crown shapes (Fig. 11a and b). The bridge framework for the mandible was formed in such a

*Framework construction*

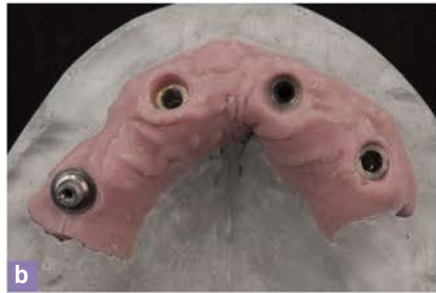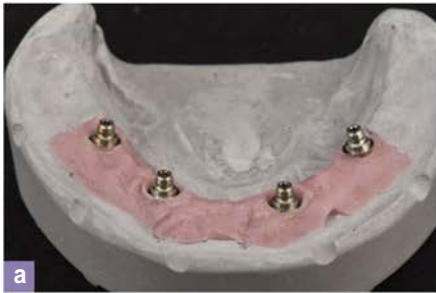


Fig. 9a and b The master models used to make the prosthetic reconstruction. A prosthesis supported with a bar was to be constructed for the maxilla. An occlusal screw-retained bridge was planned for the mandible

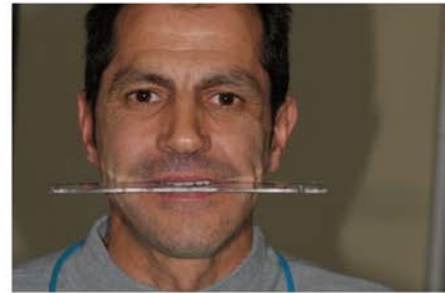

Fig. 10 Verifying the positions of the teeth in the patient's mouth. Not only aesthetic, but also functional and phonetic aspects were considered.

Fig. 11 a ad b Virtual representation of the construction in the software (mandible).

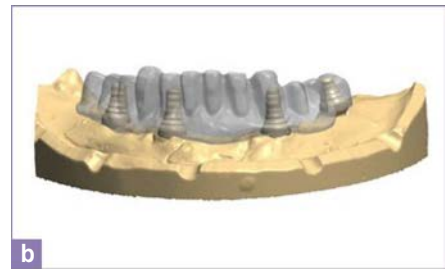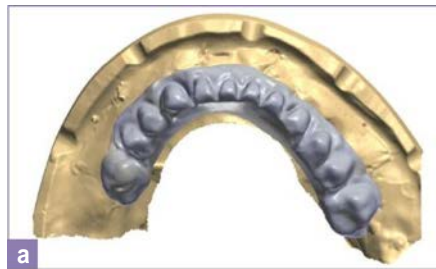
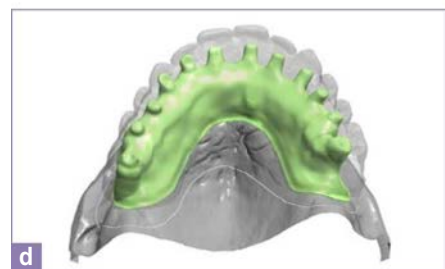

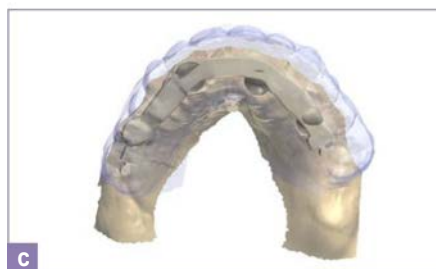
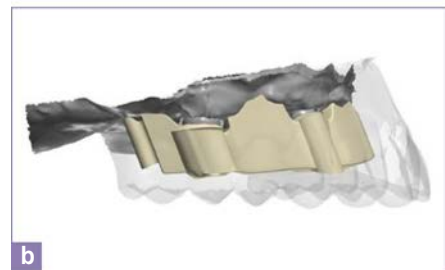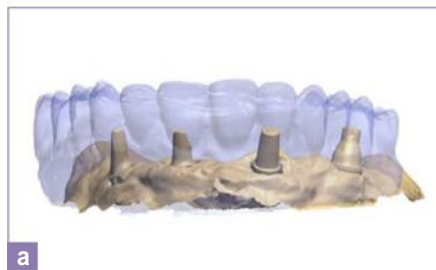Fig. 12a to d Virtual construction of the secondary structures in the maxilla based on the tooth set-up.



way as to allow the prosthesis to be finished off with ease using the veneer concept (visio.lign, bredent). The authors also used the software's transparent display to model the maxillary framework (Fig. 12a to d). The connecting bar (primary part) and bar clips (secondary part) were designed and made at the same time; this is another advantage conferred by the digitally assisted fabrication. The bases were moulded into a fully anatomical, convex shape; the PEEK material was to be in direct contact with the mucosa.

## IMPLANT PROSTHODONTICS

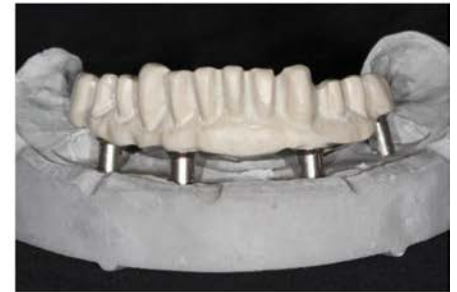

Fig. 13a and b The virtual structure was realised using CAD/CAM-assisted fabrication (PEEK, material blank: Juvora Dental Disc).

Fig. 14. The frameworks realised in PEEK.

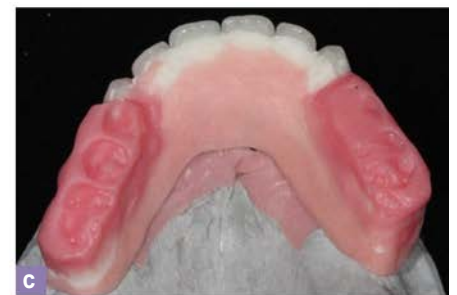
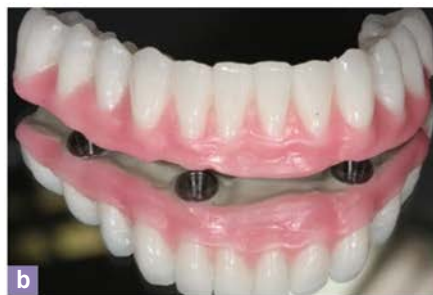
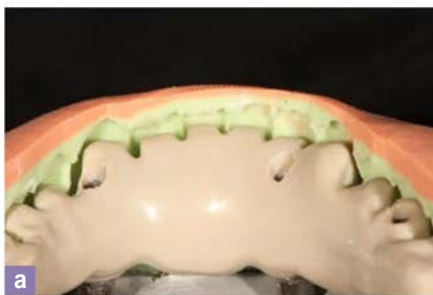Fig. 15a The dimensions of the frameworks were checked with the silicon key (mandible shown here)

Fig. 15b and c Preparations for a last wax try-in in the patient's mouth.

As is usual with CAD/CAM-assisted fabrication, the design data were transmitted to the milling machine. The construction was to be realised in PEEK; the blanks manufactured industrially for this purpose hold a CE certification for definitive, conditionally removable dentures (Fig. 13a). Milling of the structures was accomplished without any complications (Fig. 13b). The finished frameworks were an identical copy of the virtual templates.

Since the final tooth set-up was fixed with a silicon key, it was now possible to transpose the situation to the PEEK frameworks (Fig. 14). Functional aspects become particularly significant in the context of total prostheses. For this reason, bite registration should take place before the prosthesis is finished off definitively. This would also be the ideal time to review the aesthetic criteria in the patient's mouth once more. To do this, only the front teeth were set up in the maxilla, while wax walls were fitted in place of the posterior teeth (Fig. 15a to c). After another try-in, the exact bite situation was transposed into the articulator (Fig. 16) and the work completed. The framework was conditioned (primer, visio.link, bredent) and the reconstructions finished with veneers made of a high-performance polymer (visio.lign) according to the wax try-in (Fig. 17 to 20). Among other things, close attention was paid to ensuring that the undersides were given a clean finish. Any rough areas place the long-term treatment

### Finishing

## IMPLANT PROSTHODONTICS

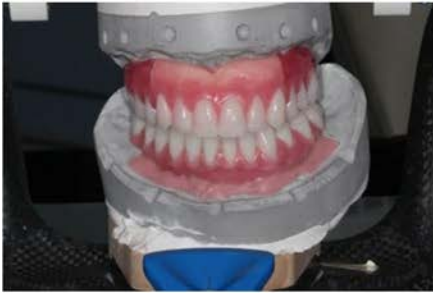

Fig. 16 After another bite check, the prostheses were transferred back to the articulator and the functional relationships precisely worked out.

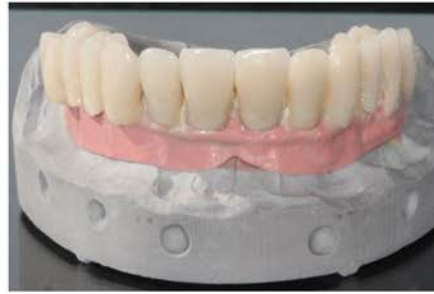

Fig. 17 Finishing the prostheses with veneers made of PMMA (visio.lign, bredent, Senden).

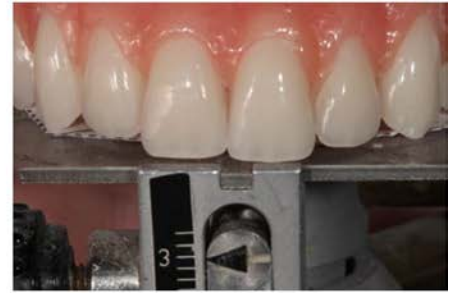

Fig. 18 Checking the occlusal plane.

Fig. 19a The finished mandibular bridge on the PEEK framework weighed only 12 grams.

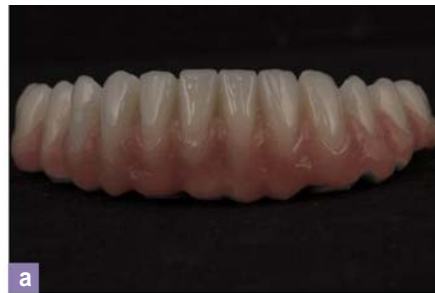

Fig. 19b Lingual view of the finished mandibular bridge.

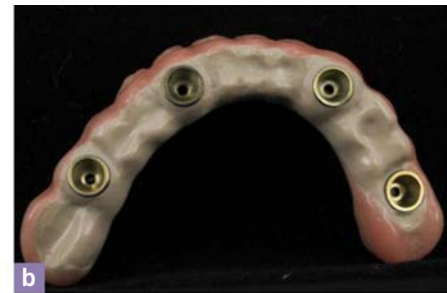
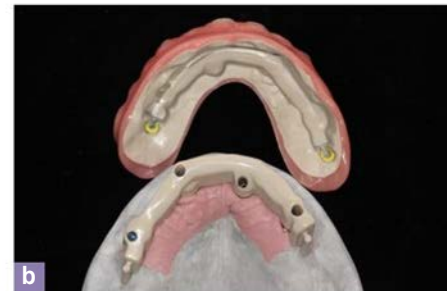
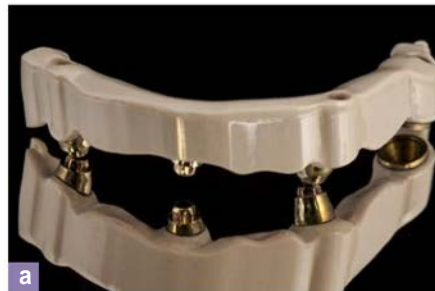Fig. 20a and b The primary bar made from PEEK and the secondary structure for the maxilla.



results at risk. In the authors' opinion, the biocompatibility and stability of PEEK in the mouth ensure that no soft tissue impairments are likely if the finish is clean.

### *Incorporation*

The occlusal screw-retained 12-unit bridge in the mandible weighed only 12 grams. The palate-less maxillary prosthesis (Fig. 21) also impressed with its low weight. Tension-free fixation of both the bar and the bridge onto the implant abutments was achieved (Fig. 22 to 25). 0° abutments (blueSKY) were used in the mandible, along with titanium screw channels glued into the PEEK bridge framework. The four implant copies were glued on in the lab. This was possible in this case, as the impression posts in the mouth were blocked with composite and the modelling plaster was separated from the impression only after the former had stopped contracting. When the bar was incorporated into the patient's mouth, tension-free fit was confirmed (with the Sheffield Test). A minimal degree of clinically undetectable incongruence was compensated for by the elasticity of the PEEK material, and not transferred to the implants or the bone.



## IMPLANT PROSTHODONTICS

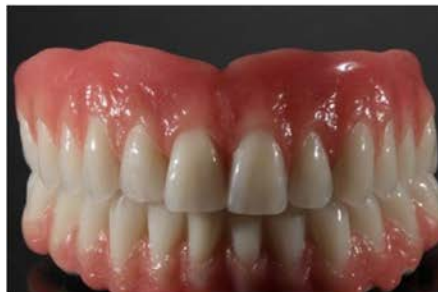

Fig. 21 First impression: this aesthetic, light and stable dental prosthesis was delivered to the practice.

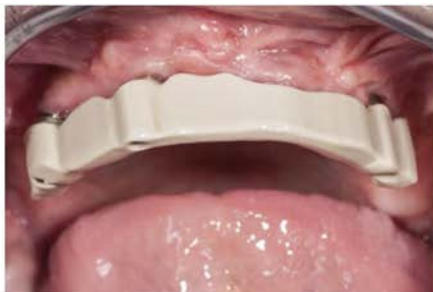

Fig. 22 and 23 Tension-free fit of the bar along with a well-integrated maxillary prosthesis.

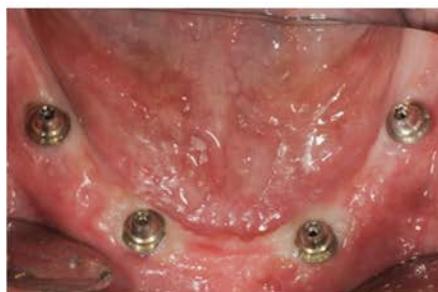
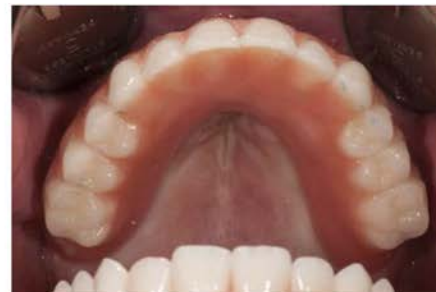
Fig. 24 and 25 A snug fit: the bridge in the lower jaw was secured to the implants with occlusal screws.

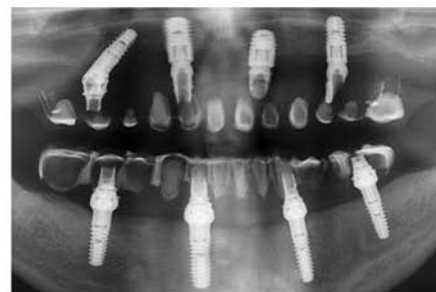
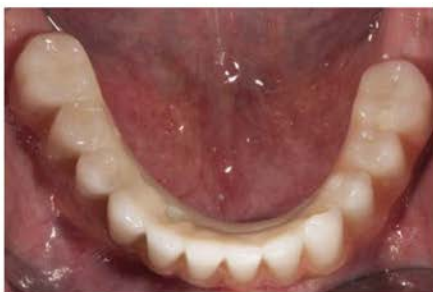

Fig. 26 The final X-ray. The PEEK material used contains no radiopaque additives (such as barium sulphate) and is thus not visible on the follow-up panoramic X-ray.

In the authors' view, this is a major advantage of this material.

The milled PEEK bar in the maxilla was also glued to the abutments in the laboratory – the implant in the region of tooth 15 carries an additional post to compensate for the 35°-degree angling (Fig. 26).

The superstructure with the secondary part made of PEEK was incorporated into the patient's mouth with a good aesthetic result and a snug fit. The running properties correspond to the sort of friction expected with conventional connecting bars or galvano internal structures. Simple removal and replacement, facilitating good denture hygiene, were guaranteed. Two weeks after the incorporation, the satisfied patient consulted the practice for a final check-up (Fig. 27 and 28).

Despite the difficult baseline situation, a considered and well-coordinated treatment concept made it possible to realise a reconstruction appropriate for the patient. The 3D-guided planning of the implantation, as well as the CAD/CAM-assisted fabrication of the prostheses provided valuable support. The PEEK material used is a further contribution towards long-term success. The material has been trialled in implants for medical indications for over ten years (Invibio PEEK-Optima) and its high biocompatibility has been confirmed in a several clinical trials.<sup>1-4</sup>

### Summary

## IMPLANT PROSTHODONTICS

Fig. 27 The situation two weeks after incorporation of the dental prosthesis.

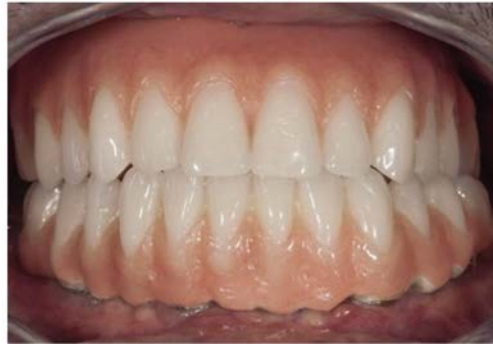

Fig. 28 The final full-face view shows a visibly satisfied patient.

PEEK has also proved its worth as a framework material in prosthetic dentistry.<sup>5</sup> Its low specific gravity, its bone-like elasticity and its toughness, combined with an almost total lack of material fatigue make it an ideal player in prosthodontics. The option of CAD/CAM-assisted processing of PEEK gives rise to many possibilities, both from the patient's and the treatment team's point of view. So far, the material is restricted to removable and conditionally removable dental prostheses. This means that the described material can be used to make model-cast prostheses, secondary parts, superstructures for combined dental reconstructions, screw-retained full crowns in aesthetically unimportant areas (posterior teeth) and conditionally removable, screw-retained bridges.

*Acknowledgments* The authors' thanks for the technical realisation go to Master Dental Technician Florian Rießenberger (CAD/ CAM specialist) and Dental Technician Markus Smode (realisation of the veneers and finishing). They would like to thank the whole team at Clínica Somosaguas for their outstanding patient care.

- References*
1. Aaron R, Cutler AR, Saquib Siddiqui MD, et al. Comparison of polyetheretherketone cages with femoral cortical bone allograft as a single-piece interbody spacer in transforaminal lumbar interbody fusion. *J Neurosurg* 2006;5:534–539.
  2. Capps SG. PEEK Cages and Spacers in Cervical Spine Fusion Applications. *Spinal News International* 2007;September:4.
  3. Celik SE, Kara A, Celik S. A Comparison of Changes Over Time in Cervical Foraminal Height After Tricortical Iliac Graft or Polyetheretherketone Cage Placement Following Anterior Discectomy. *J Neurosurg* 2007;6:10–16.
  4. Kurtz SM, Devine JN. PEEK biomaterials in trauma, orthopedic, and spinal implants. *Biomater* 2007;28:4845–4869.
  5. Siewert B, Parra M. Eine neue Werkstoffklasse in der Zahnmedizin. PEEK als Gerüstmaterial bei 12-gliedrigen implantatgetragenen Brücken. *Z Zahnärztl Implantol* 2013;29:148–159.



Dr. Bernd Siewert  
Calle Aquilón, 2 Local 7/8  
28223 Pozuelo de Alarcón  
[E-Mail: Siewert@dental-med.com](mailto:Siewert@dental-med.com)



ZTM Helmut Rieger  
Am Backofenwall 3  
86153 Augsburg  
[E-Mail: info@rieger-zahntechnik.de](mailto:info@rieger-zahntechnik.de)

